

**PATIENT**

Isabella Ullman

**SPECIES**

Canine

**BREED**

Aus Shep Mix

**SEX**

FS

**AGE**

9yr

**WEIGHT**

42.5lb

**INTERPRETED BY**

Remo Lobetti, BVSc,  
 MMedVet (Med), PhD,  
 Dipl. ECVIM

**IMAGING PERFORMED BY**

Kathleen Byrnes

**HOSPITAL NAME**

Armstrong Animal  
 Clinic

**REFERRING VET**

Dr Dolan

**INVOICE**  
 25020

**DATE**  
 06/05/2026

**PRESENTING CLINICAL SIGNS**

P presented for ultrasound to evaluate a chronic intermittent history of vomiting. Does not appear to be associated with bilious vomiting. happens at random times. Concern for delayed gastric emptying, motility issue?

**ULTRASONOGRAPHIC EXAMINATION OF THE ABDOMEN**

**Urinary System**

Small urinary bladder with a normal thickness and smooth appearance of the wall. Normal anechoic urine with no sediment or uroliths evident.

Normal appearance of the trigone area, proximal urethra, and iliac blood vessels.

Normal appearance and size of the iliac lymph nodes. Ureters not visualized, which can be considered a normal finding.

Normal renal size, architecture, echogenic appearance, cortico-medullary differentiation, which maintains a 1:3 cortex to medulla ratio, pelvis, and capsule. No infarcts, mineralization or renoliths evident.

The left kidney measured 5.2 cm in length.

The right kidney measured 5.8 cm in length.

**Adrenal Glands**

Normal shape, echogenic appearance, size, position, and appearance of the visible peri-renal vasculature.

The left adrenal gland measured 1.66 cm x 0.5 cm x 0.43 cm.

The right adrenal gland measured 1.67 cm x 0.64 cm.

**Spleen**

Normal size and echogenic appearance. Smooth homogenous parenchyma and regular curvilinear capsule. Normal volume of the splenic vasculature without any overt congestion or thrombosis evident. No inflammatory, neoplastic, infarction, or infiltrative changes evident.

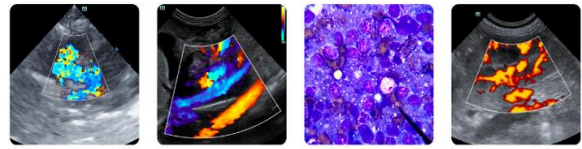
**Liver**

Normal size, echogenic appearance, portal markings, and regular curvilinear capsule. No nodules or masses evident. Normal appearance of the hepatic and portal vasculature. The spleen measured 2.0 cm in width.

**Gallbladder**

Small containing normal anechoic bile. Normal thickness and echogenic appearance of the wall. Normal size and appearance of the cystic and common bile duct.

**Gastrointestinal**



**PATIENT**

Isabella Ullman

Normal appearance of the stomach, duodenum, small intestine, ileo-cecal junction, and colon with no loss of layering, 1:3 muscularis to mucosa ratio, normal wall thickness and peristaltic activity, and no distension of the lumen. Large amount of ingesta present within the stomach.

**SPECIES**

Canine

***Pancreas***

Normal size and echogenic appearance. Regular capsule. Normal echogenic appearance of the mesentery and fat surrounding the pancreas.

**BREED**

Aus Shep Mix

***Free Abdomen***

Normal mesenteric lymph nodes.

No ascites evident.

**SEX**

FS

**ULTRASONOGRAPHIC FINDINGS**

- Ingesta full stomach

**AGE**

9yr

**INTERPRETATION OF THE FINDINGS & FURTHER RECOMMENDATIONS**

As the patient was fasted for ~ 12 hours, the presence of ingesta within the stomach is an abnormal finding, with possible etiologies being chronic gastritis, helicobacter gastritis, and gastric hypomotility. On this ultrasound, there is no obvious pyloric obstruction evident. Further assessment would be endoscopy of the upper GI tract with biopsies.

**WEIGHT**

42.5lb

Initial management of possible gastric hypomotility would be the use of prokinetic agents, such as metoclopramide and cisapride, as well as feeding small frequent meals of an intestinal type diet.

**INTERPRETED BY**

Remo Lobetti, BVSc,  
MMedVet (Med), PhD,  
Dipl. ECVIM

**IMAGING  
PERFORMED BY**

Kathleen Byrnes

**HOSPITAL NAME**

Armstrong Animal  
Clinic

**REFERRING VET**

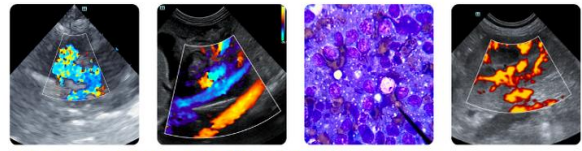
Dr Dolan

**INVOICE**

25020

**DATE**

06/05/2026



**PATIENT**

Isabella Ullman

**SPECIES**

Canine

**BREED**

Aus Shep Mix

**SEX**

FS

**AGE**

9yr

**WEIGHT**

42.5lb

**INTERPRETED BY**

Remo Lobetti, BVSc,  
 MMedVet (Med), PhD,  
 Dipl. ECVIM

**IMAGING PERFORMED BY**

Kathleen Byrnes

**HOSPITAL NAME**

Armstrong Animal  
 Clinic

**REFERRING VET**

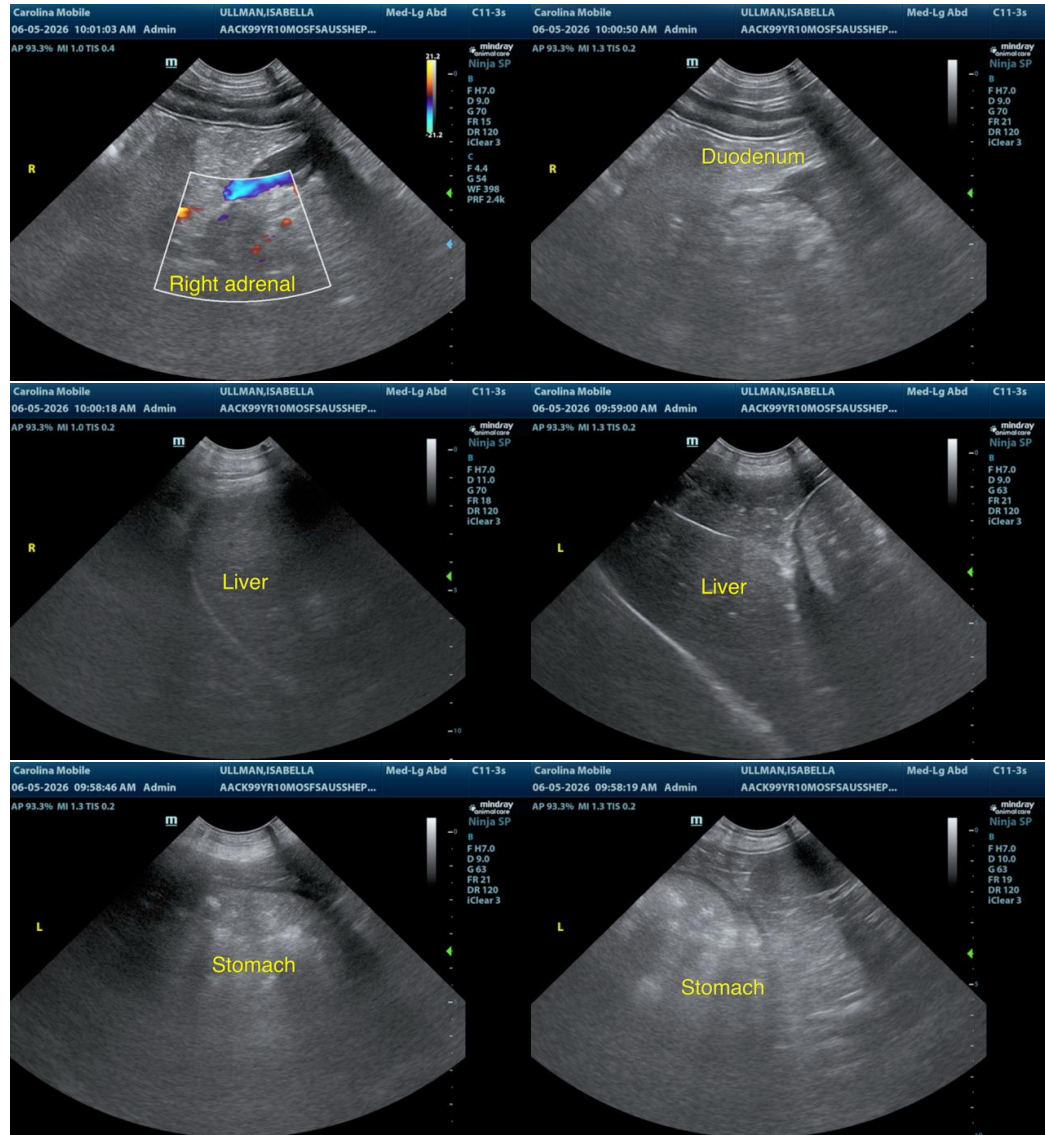
Dr Dolan

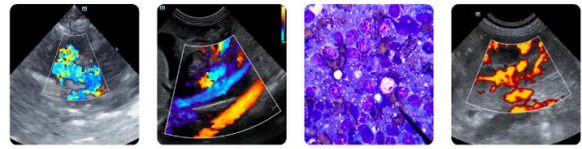
**INVOICE**

25020

**DATE**

06/05/2026





**PATIENT**

Isabella Ullman

**SPECIES**

Canine

**BREED**

Aus Shep Mix

**SEX**

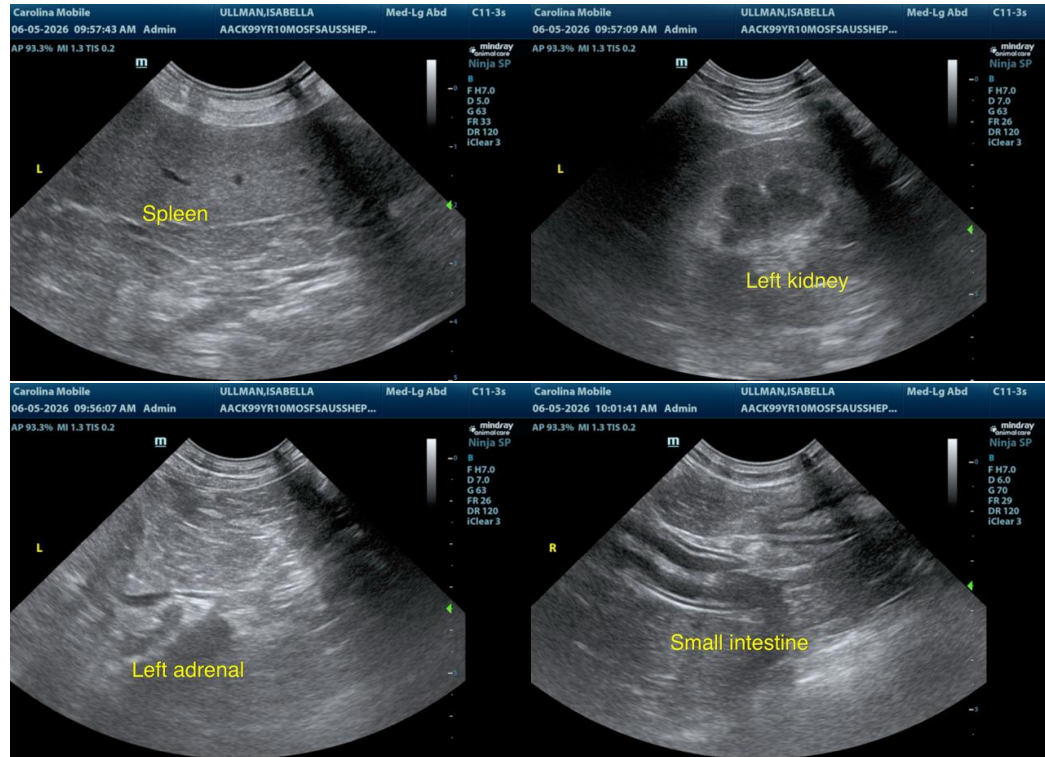
FS

**AGE**

9yr

**WEIGHT**

42.5lb



**INTERPRETED BY**

Remo Lobetti, BVSc, MMedVet (Med), PhD, Dipl. ECVIM

The information and recommendations provided are based on the images presented by the referring veterinarian. No evaluation can be communicated regarding pathology that was not visible in the image/video clips provided.

Thank you for this referral. If the clinical or image interpretation does not parallel your findings or if I can be of any further assistance, please contact me.

**IMAGING PERFORMED BY**

Kathleen Byrnes

Remo Lobetti, BVSc, MMedVet (Med), PhD, Dipl. ECVIM (Internal Medicine)

**HOSPITAL NAME**

Armstrong Animal Clinic

[info@sonopath.com](mailto:info@sonopath.com)

**REFERRING VET**

Dr Dolan

**INVOICE**

25020

**DATE**

06/05/2026